

# Rapid Palatal Expansion in Mixed Dentition Using a Modified Expander: a Cephalometric Investigation

PAOLA COZZA, M.D., D.D.S., M.S.

ALDO GIANCOTTI, D.D.S., M.S.

ANTONIA PETROSINO, D.D.S.

Department of Orthodontics, University of Rome 'Tor Vergata', Via di Tor Vergata, 135-00173 Rome, Italy

**Abstract.** The aims of this investigation were to cephalometrically study the short-term skeletal and dental modifications induced by rapid palatal expansion in a sample of 20 patients (10 male, 10 female), aged 6–10 years (mean age 8 years) in mixed dentition with a uni- or bilateral posterior crossbite, a mild skeletal Class II malocclusion, and an increased vertical dimension (FMA, SN<sup>∧</sup>GoGn), and to compare them with an untreated matched control group of 20 subjects (10 male and 10 female), mean age 8 years.

Cephalometric analysis showed that the maxilla displayed a tendency to rotate downwards and backward, resulting in a statistically significant increase of the SN<sup>∧</sup>PP angle ( $T_0 = 9.95$  degrees,  $T_1 = 11.60$  degrees,  $P < 0.01$ ) and the SN-ANS linear value ( $T_0 = 49.50$  mm,  $T_1 = 51.10$  mm,  $P < 0.05$ ).

In addition, there was a statistically significant alteration of the anterior total facial height N-Me ( $T_0 = 113.15$  mm,  $T_1 = 114.15$  mm,  $P < 0.05$ ) and for the dental upper molar measurement U6-PP ( $T_0 = 19.70$  mm,  $T_1 = 20.30$  mm,  $P < 0.05$ ).

The small alterations found in the anterior total facial height and in the sagittal angles agree with previous studies, and suggest that RPE can be also used in subjects with a tendency to vertical growth and a skeletal Class II malocclusion.

*Index words:* Maxillary expansion, Mixed dentition, Cephalometric investigation.

## Introduction

Rapid palatal expansion (RPE) performed in the early stages of occlusal development has become an accepted orthodontic practice when orthopaedic opening of both halves of the maxillary process is required (da Silva *et al.*, 1995).

Although the use of RPE procedures in the primary and mixed dentition has been reported in the literature, and the clinical indications have been proposed (Bell, 1982; Bishara *et al.*, 1987; Nicholson *et al.*, 1989; Halazonetis *et al.*, 1994), relatively little has been published concerning the specific cephalometric alterations induced by this appliance. Haas (1970) stated that once the mid-palatal suture opens, the maxilla always moves forward and downward, and this causes a downward and backward rotation of the mandible, which decreases the effective length of the mandible and increases the vertical dimension of the lower face.

Wertz (1970) suggested from his analysis of lateral cephalograms that the maxilla drops down consistently, but rarely moves forward significantly. However, he had no control group against which to assess the vertical changes.

This was later confirmed by da Silva *et al.* (1991), who found that the maxilla did not show any statistically significant alterations in the anteroposterior position over the

14–16 days of appliance activator. The maxilla displayed a tendency to rotate downward and backward increasing the SN-PP angle value. The mandible rotated down and posteriorly.

McNamara (1993) in a study of the effects induced by a RPE appliance observed that widening the maxilla lead to a spontaneous forward posturing of the mandible during the retention period and that a spontaneous correction of Class II relationship can be found after 6–12 months.

Velázquez *et al.* (1996) in a long-term study regarding the effects of RPE reported that the modest, but potentially unfavourable changes induced by the RPE device, such as an open bite or mandibular postero-rotation, are reversible. They found that, following termination of orthodontic treatment, these undesirable effects were almost completely resolved.

This study aims to evaluate the short-term cephalometric alterations induced by a new RPE appliance recently presented in the literature (Cozza *et al.*, 1999), and specifically used in subjects in the mixed dentition with a uni- or bilateral posterior crossbite, a mild skeletal Class II malocclusion and an increased vertical dimension.

## Subjects and methods

The sample comprised 20 patients (10 male and 10 female) with an age range of 6–10 years (mean age 8 years).

Correspondence: Dr Aldo Giancotti, Via Barnaba Tortolini 5, 00197 Rome, Italy

All children showed either a uni- or bilateral posterior crossbite with a transverse deficiency, the average presented a skeletal Class II malocclusion and a vertical growth pattern.

Twenty subjects, 10 males and 10 females (mean age 8 years), with untreated uni- or bilateral posterior crossbites were selected from the files of the Department of Orthodontics of the University of Rome 'Tor Vergata' to comprise the control group.

The expansion procedure was carried out with a new RPE fixed appliance (Butterfly expander) routinely used by the authors in the mixed dentition for patients with transverse maxillary deficiency. In this expander, the screw is assembled with two round stainless steel wires (arms), soldered to bands placed on the second primary molars (Figure 1)

Activation of the screw commenced immediately after the appliance was cemented in place with a complete turn of the screw (four one-quarter turns). The parents were instructed to activate a one-quarter turn three times a day (morning, afternoon, evening). The activation period lasted from 7 to 9 days depending primarily on the degree of maxillary constriction. The lateral expansion of the upper arch was deemed sufficient when the posterior crossbite was overcorrected by 2–3 mm for each side. The appliance was left *in situ* passively for 6 months and its screw was sealed to prevent unwinding.

The alterations produced by the RPE appliances were assessed on two lateral cephalometric radiographs (T0–T1). The first cephalogram was taken before treatment and the second immediately after removal of the RPE appliance; the average time between radiographs was approximately 6 months.

Two radiographs were also taken in a control group and the average interval was approximately 8 months. Linear and angular cephalometric measurements were used for this study.

#### Sagittal analysis

SNA angle, SNB angle, ANB angle, AO–BO mm, N perp.–A mm (point A to nasion perpendicular), N perp.–Pg mm (point Pg to nasion perpendicular), PTM–A mm (perpendicular distance from point A to pterygomaxillary vertical line) (Figure 2).

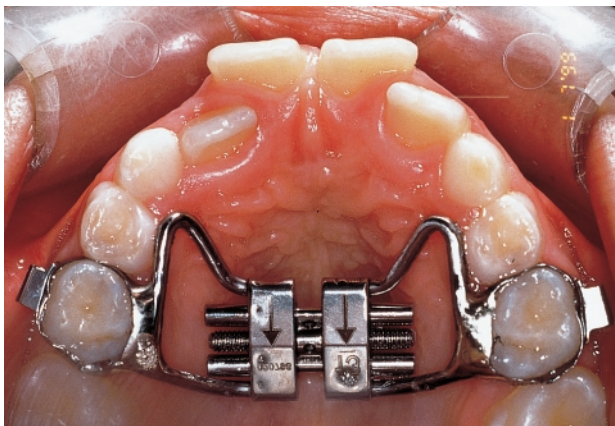


FIG. 1 'Butterfly' fixed expander used for the maxillary widening.

#### Vertical analysis

FMA angle, SN<sup>^</sup>GoGn angle, PP<sup>^</sup>GoGn angle, SN<sup>^</sup>PP angle, P.occl.<sup>^</sup>FH angle, Ar–Go mm, PP–Me mm, (S–Go)/(N–Me) per cent, S–Go mm, N–Me mm, SN–PNS mm (perpendicular distance from sella–nasion plane to posterior nasal spine), SN–ANS mm (perpendicular distance from sella–nasion plane to anterior nasal spine), GoMe–PNS mm (perpendicular distance from gonion–menton plane to posterior nasal spine), GoMe–ANS mm (perpendicular distance from gonion–menton plane to anterior nasal spine) (Figure 3).

#### Dental analysis

IMPA angle, inc.sup.<sup>^</sup>FH angle, inter-incisal angle, U6–PP mm (perpendicular distance from palatal plane to mesial cusp tip of maxillary first molar), L6–MP mm (perpendicular distance from mandibular plane to mesial cusp tip of mandibular first molar) (Figure 4).

#### Method error

Each cephalogram was traced and measured by one of the authors (P.C.). All measurements were repeated after a period of 7 days and the mean value of the two measurements was used.

All measurement error coefficients were found to be close to 1.00 and within acceptable limits (Table 1).

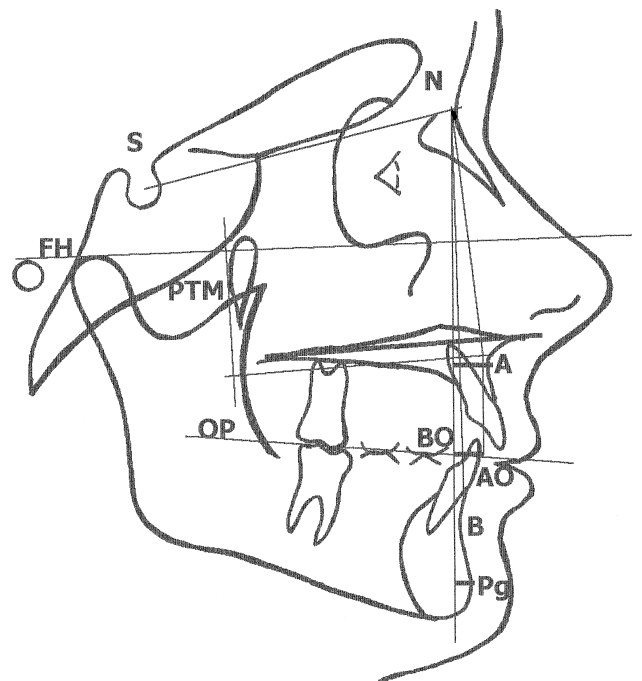


FIG. 2 Sagittal analysis: cephalometric landmarks. S (sella), N (nasion), A (Downs A point), B (Downs B point), AO (point A to occlusal plane perpendicular), BO (point B to occlusal plane perpendicular), Pg (pogonion), PTM (pterygomaxillary fissure), FH (Frankfort horizontal plane), OP (occlusal plane).

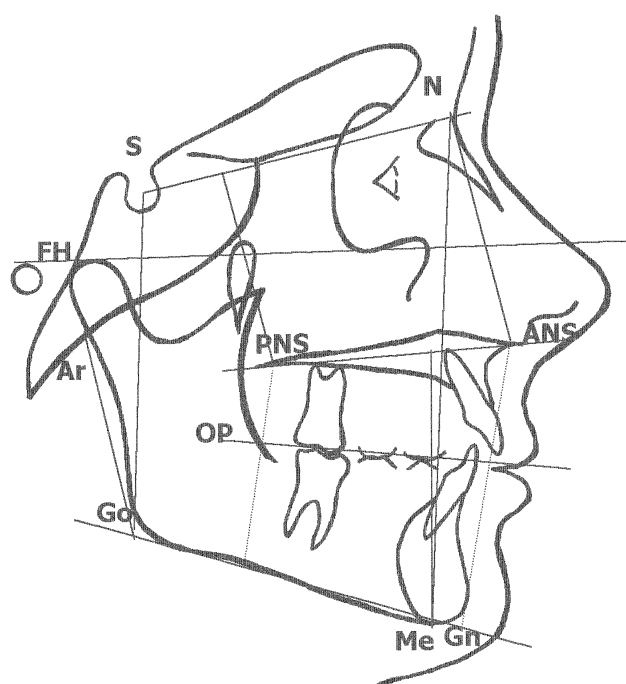


FIG. 3 Vertical analysis: cephalometric landmarks. S (sella), N (nasion), ANS (anterior nasal spine), PNS (posterior nasal spine), FH (Frankfort horizontal plane), OP (occlusal plane), Ar (articulare), Go (gonion), Me (menton), Gn (gnathion).

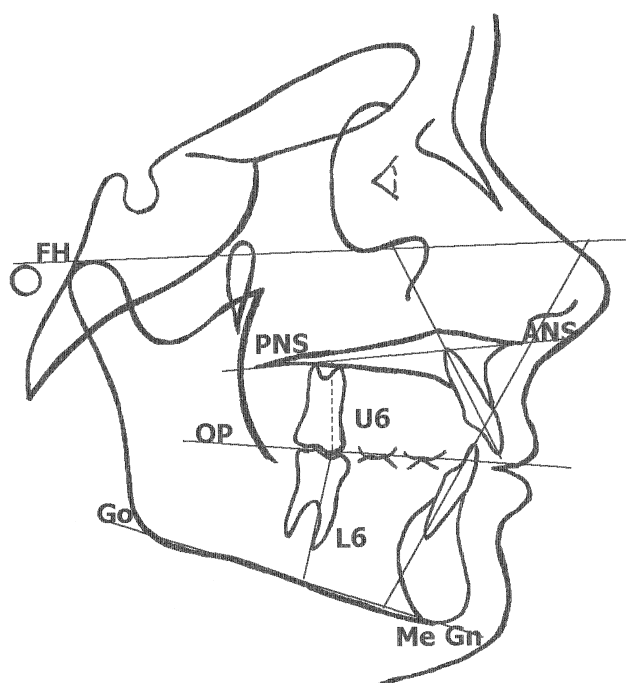


FIG. 4 Dental analysis: cephalometric landmarks. ANS (anterior nasal spine), PNS (posterior nasal spine), FH (Frankfort horizontal plane), OP (occlusal plane), Go (gonion), Me (menton), Gn (gnathion), U6 (upper first molar), L6 (lower first molar).

TABLE 1 Method error coefficients

Variables	R
SNA (°)	0.99
SNB (°)	0.98
ANB (°)	0.98
AO-BO (mm)	0.99
N perp.-A (mm)	0.99
N perp.-Pg (mm)	0.99
PTM-A (mm)	0.97
FMA (°)	0.98
SN^GoGn (°)	0.98
PP^GoGn (°)	0.99
SN^PP (°)	0.97
Poccl. ^ FH (°)	0.99
Ar-Go (mm)	0.98
PP-Me (mm)	0.98
(S-Go)/(N-Me) (%)	0.97
S-Go (mm)	0.99
N-Me (mm)	0.99
SN-PNS (mm)	0.98
SN-ANS (mm)	0.98
GoMe-PNS (mm)	0.97
GoMe-ANS (mm)	0.97
IMPA (°)	0.99
Inc.sup. ^ FH (°)	0.99
Interincisal angle (°)	0.97
U6-PP (mm)	0.97
L6-MP (mm)	0.98

#### Statistical method

Descriptive statistics including mean and standard deviation. The mean differences in cephalometric measurements at T0 and T1 were examined with Wilcoxon's test. We used a non-parametric test because the studied variables were not normally distributed.

#### Results

Table 2 shows a comparison between the initial cephalometric values for the control group and the treated group. No statistically significant differences were found although several mean differences of clinically significant size are found.

Table 3 shows the comparison for each cephalometric measurement considered before (T0) and after treatment (T1) with RPE and the four variables in which the RPE procedure induced statistically significant ( $P < 0.05$ ) alterations.

Table 4 shows the mean and standard deviation for the cephalometric measurement in the control group.

The RPE procedures induced statistically significant alterations only in four cephalometric measurements: SN^PP, SN-ANS, N-Me, and U6-PP. The SN^PP angle value increased (T0 = 9.95, T1 = 11.60) as did the SN-ANS linear value (T0 = 49.50, T1 = 51.10), which resulted in a downward and backward displacement of the palatal plane (the distance between the SN plane and point PNS also increased, but not statistically).

An increase of the anterior total facial height N-Me (T0 = 113.15, T1 = 114.15) and the dental molar measurement U6-PP (T0 = 19.70, T1 = 20.30) was noted, and this caused a downward and backward rotation of the mandible.

## Discussion

A comparison between the results obtained from different studies was difficult, due to the lack of data concerning the age, the dental and skeletal Class relationship, the cephalo-

metric analysis adopted and the type of growth pattern of the examined subjects.

TABLE 2 Comparison between control group and treated group—initial values

Variables	T0 control group	SD0	T0 treated group	SD0	P
SNA (°)	80.25	1.36	78.02	3.61	NS
SNB (°)	76.25	1.38	74.47	3.27	NS
ANB (°)	4.00	0.75	3.80	2.68	NS
AO-BO (mm)	1.38	1.38	1.35	3.95	NS
N perp.-A (mm)	0.25	1.39	-1.15	2.87	NS
N perp.-Pg (mm)	-3.75	2.49	-8.10	5.87	NS
PTM-A (mm)	48.62	1.99	49.63	4.32	NS
FMA (°)	26.75	1.66	28.60	4.86	NS
SN ^ GoGn (°)	37.56	2.94	37.90	4.81	NS
PP^GoGn (°)	28.19	1.46	28.05	5.52	NS
SN ^ PP (°)	8.62	2.98	9.95	3.76	NS
Poccl. ^ FH (°)	10.75	2.25	11.10	2.88	NS
Ar-Go (mm)	38.62	2.44	38.70	3.45	NS
PP-Me (mm)	56.13	3.64	61.15	4.41	NS
(S-Go)/(N-Me) (%)	61.42	1.81	59.60	3.21	NS
S-Go (mm)	64.87	2.64	67.55	4.66	NS
N-Me (mm)	105.63	4.62	113.15	6.99	NS
SN-PNS (mm)	40.62	1.60	41.40	2.37	NS
SN-ANS (mm)	49.50	3.42	49.50	3.34	NS
GoMe-PNS (mm)	38.50	3.34	39.25	2.91	NS
GoMe-ANS (mm)	59.00	3.33	62.55	4.85	NS
IMPA (°)	89.75	2.12	91.90	6.12	NS
Inc.sup. ^ FH (°)	110.13	6.31	111.35	7.14	NS
Interincisal angle (°)	136.13	5.69	126.80	11.69	NS
U6-PP (mm)	17.62	2.02	19.70	2.02	NS
L6-MP (mm)	26.88	4.19	27.20	1.73	NS

### Antero-posterior alterations of the apical bases

In the present study it was found that there were no statistically significant alterations in the antero-posterior position of the maxilla, which contradicts the conclusions of Davis and Kronman (1969) and Haas (1970), but it is in agreement with Byrom (1971), Sarver and Johnston (1989), and da Silva *et al.* (1991). No statistically significant changes were observed in the control group.

### Vertical alterations of the apical base and facial height

Vertical changes raised from this study agree with those reported by Davis and Kronman (1969), Wertz (1970), Byrom (1971), Sarver and Johnston (1989), da Silva *et al.* (1991), Velázquez *et al.* (1996), Asanza *et al.* (1997), and Akkaya *et al.* (1999).

Downward and backward (SNB, N perp.-Pg) displacement of the apical base results in a slight, and not significant rotation of the palatal and mandibular plane. The first is responsible for the statistically significant increase in SN^PP angle value and linear distance SN-ANS, and the second for the increase in anterior total facial height N-Me. No statistically significant modifications of the skeletal divergency angles (FMA, SN^GoGn) were found.

The minimum increase of the facial anterior heights is a direct effect of extrusion of anchoring primary upper molars.

No statistically significant changes were observed in the control group.

TABLE 3 Cephalometric changes with treatment in the RPE group

Variables	T0	SD0	T1	SD1	Mean of changes	SD of changes	P
SNA (°)	78.02	3.61	77.85	2.79	-0.17	1.77	NS
SNB (°)	74.47	3.27	73.90	2.75	-0.57	1.79	NS
ANB (°)	3.80	2.68	3.90	2.76	0.10	0.79	NS
AO-BO (mm)	1.35	3.95	1.45	3.06	0.10	1.55	NS
N perp.-A (mm)	-1.15	2.87	-1.15	3.45	0.00	2.55	NS
N perp.-Pg (mm)	-8.10	5.87	-8.45	5.72	-0.35	2.87	NS
PTM-A (mm)	49.63	4.32	50.36	3.77	0.74	1.59	NS
FMA (°)	28.60	4.86	28.25	5.11	-0.35	2.56	NS
SN ^ GoGn (°)	37.90	4.81	38.45	4.59	0.55	2.72	NS
PP^GoGn (°)	28.05	5.52	27.25	4.19	-0.80	2.69	NS
SN ^ PP (°)	9.95	3.76	11.60	3.25	1.65	2.64	**
Poccl. ^ FH (°)	11.10	2.88	10.70	3.74	-0.40	2.56	NS
Ar-Go (mm)	38.70	3.45	39.80	3.62	1.10	2.31	NS
PP-Me (mm)	61.15	4.41	61.90	4.77	0.75	1.97	NS
(S-Go)/(N-Me) (%)	59.60	3.21	59.40	2.60	-0.20	2.02	NS
S-Go (mm)	67.55	4.66	67.75	3.80	0.20	1.82	NS
N-Me (mm)	113.15	6.99	114.15	6.88	1.00	2.18	*
SN-PNS (mm)	41.40	2.37	41.75	2.24	0.35	1.69	NS
SN-ANS (mm)	49.50	3.34	51.10	3.46	1.60	2.33	*
GoMe-PNS (mm)	39.25	2.91	39.70	3.26	0.45	2.28	NS
GoMe-ANS (mm)	62.55	4.85	63.05	4.65	0.50	1.88	NS
IMPA (°)	91.90	6.12	91.30	6.47	-0.60	4.01	NS
Inc.sup. ^ FH (°)	111.35	7.14	111.45	7.44	0.10	4.44	NS
Interincisal angle (°)	126.80	11.69	128.65	10.40	1.85	6.23	NS
U6-PP (mm)	19.70	2.02	20.30	2.20	0.60	1.14	*
L6-MP (mm)	27.20	1.73	27.55	2.25	0.35	1.14	NS

\* $P < 0.05$ ; \*\* $P < 0.01$ .



TABLE 4 Cephalometric changes in the control group over the observation period

Variables	T0	SD0	T1	SD1	Mean of changes	SD of changes	P
SNA (°)	80.25	1.36	80.37	1.16	0.12	1.73	NS
SNB (°)	76.25	1.38	76.19	1.36	-0.6	1.84	NS
ANB (°)	4.00	0.75	4.18	1.03	0.18	0.69	NS
AO-BO (mm)	1.38	1.38	1.69	1.62	0.31	1.64	NS
N perp.-A (mm)	0.25	1.39	0.06	1.52	-0.19	2.31	NS
N perp.-Pg (mm)	-3.75	2.49	-2.85	3.77	0.9	2.56	NS
PTM-A (mm)	48.62	1.99	48.62	2.11	0.00	1.46	NS
FMA (°)	26.75	1.66	26.94	1.52	0.19	2.61	NS
SN ^ GoGn (°)	37.56	2.94	37.56	3.09	0.00	2.70	NS
PP ^ GoGn (°)	28.19	1.46	28.06	1.52	-0.13	2.70	NS
SN ^ PP (°)	8.62	2.98	8.75	3.02	0.13	2.58	NS
Poccl. ^ FH (°)	10.75	2.25	10.75	2.24	0.00	2.44	NS
Ar-Go (mm)	38.62	2.44	38.69	2.55	0.07	2.22	NS
PP-Me (mm)	56.13	3.64	56.06	3.62	-0.07	2.11	NS
(S-Go)/(N-Me) (%)	61.42	1.81	61.29	2.99	-0.13	1.99	NS
S-Go (mm)	64.87	2.64	65.00	2.93	0.13	1.81	NS
N-Me (mm)	105.63	4.62	106.06	4.57	0.43	2.16	NS
SN-PNS (mm)	40.62	1.60	40.75	1.69	0.13	1.56	NS
SN-ANS (mm)	49.50	3.42	49.50	3.42	0.00	2.31	NS
GoMe-PNS (mm)	38.50	3.34	38.50	3.34	0.00	2.15	NS
GoMe-ANS (mm)	59.00	3.33	58.93	3.21	-0.07	1.75	NS
IMPA (°)	89.75	2.12	90.13	2.15	0.38	3.99	NS
Inc.sup. ^ FH (°)	110.13	6.31	110.19	6.41	-0.06	4.29	NS
Interincisal angle (°)	136.13	5.69	135.75	6.04	-0.38	6.11	NS
U6-PP (mm)	17.62	2.02	17.50	1.41	-0.12	1.12	NS
L6-MP (mm)	26.88	4.19	26.94	4.20	0.12	1.18	NS

## Conclusions

Based on the cephalometric alterations observed after RPE during mixed dentition, the following can be concluded:

1. No statistically significant changes were observed in the sagittal analysis.
2. No statistically significant changes were observed in FMA and SN ^ GoGn angle.
3. The palatal plane displayed a slight downward and backward rotation altering: SN ^ PP, SN-ANS.
4. A statistically significant increase of the dental molar measurement U6-PP was noted.
5. A statistically significant increase in the anterior total facial height (N-Me) was observed as a direct effect of the vertical displacement of the palatal plane and the upper molars.

In all subjects a satisfactory resolution of the maxillary constriction was obtained, which indicates that this procedure can also be used in patients with a tendency to vertical growth, considering the minimum increase of the N-Me verified.

6. Previous studies would suggest that these modest short-term changes are reversible.

## References

**Akkaya, S., Lorenzon, S. and Ucem, T. T. (1999)**

A comparison of sagittal and vertical bonded rapid and slow maxillary expansion procedures, *European Journal of Orthodontics*, **21**, 175-180.

**Asanza, S., Cisneros, G. J. and Nieberg, L. G. (1997)**

Comparison of Hyrax and bonded expansion appliances, *Angle Orthodontist*, **67**, 15-22.

**Bell, R. A. (1982)**

A review of maxillary expansion in relation to rate of expansion and patient's age, *American Journal of Orthodontics*, **81**, 32-37.

**Bishara, S. E. and Staley, R. N. (1987)**

Maxillary expansion: clinical implications, *American Journal of Orthodontics*, **91**, 3-14.

**Byrom, A. G. (1971)**

Evaluation of anterior-posterior and vertical skeletal changes in rapid palatal expansion cases as studied by lateral cephalograms, *American Journal of Orthodontics and Dentofacial Orthopedics*, **60**, 419.

**Cozza, P., Giaccotti, A. and Petrosino, A. (1999)**

Butterfly expander for use in mixed dentition, *Journal of Clinical Orthodontics*, **33**, 583-587.

**da Silva, O. G., Villas Boas, M. C. and Capelozza, L. (1991)**

Rapid maxillary expansion in the primary and mixed dentitions: a cephalometric evaluation, *American Journal of Orthodontics*, **100**, 171-181.

**Davis, M. W. and Kronman, J. H. (1969)**

Anatomical changes induced by splitting of the midpalatal suture, *Angle Orthodontist*, **39**, 126-132.

**Haas, A. J. (1970)**

Palatal expansion: just the beginning of dentofacial orthopedics, *American Journal of Orthodontics*, **57**, 219-255.

**Halazonetis, D. J., Katsavrias, E. and Spyropoulos, M. N. (1994)**

Changes in cheek pressure following rapid maxillary expansion, *European Journal of Orthodontics*, **16**, 295-300.

**McNamara, J. A. (1993)**

*Orthodontic and orthopedic treatment in the mixed dentition*, Needham Press Inc, Ann Arbor.

**Nicholson, P. T. and Plint, D. A. (1989)**

A long-term study of rapid maxillary expansion and bone grafting in cleft lip and palate patients,  
*European Journal of Orthodontics*, **11**, 186–192.

**Sarver, D. M. and Johnston, M. W. (1989)**

Skeletal changes in vertical and anterior displacement of the maxilla with bonded rapid palatal expansion appliances,  
*American Journal of Orthodontics and Dentofacial Orthopedics*, **95**, 462–466.

**Velázquez, P., Benito, E. and Bravo, L. A. (1996)**

Rapid maxillary expansion. A study of the long-term effects,  
*American Journal of Orthodontics*, **109**, 361–367.

**Wertz, R. A. (1970)**

Skeletal and dental changes accompanying rapid midpalatal suture opening,  
*American Journal of Orthodontics*, **58**, 41–66.